

Amyloidosis of the head and neck: a clinicopathological study of cases with long-term follow-up

Wioletta Pietruszewska¹, Małgorzata Wągrow ska-Danilewicz², Janusz Klatka³

¹Department of Otolaryngology and Laryngological Oncology, Medical University of Lodz, Poland

²Department of Nephropathology, Medical University of Lodz, Poland

³Department of Otolaryngology and Laryngological Oncology, Medical University of Lublin, Poland

Submitted: 12 February 2012

Accepted: 17 June 2012

Arch Med Sci 2014; 10, 4: 846–852

DOI: 10.5114/aoms.2013.39206

Copyright © 2014 Termedia & Banach

Corresponding author:

Wioletta Pietruszewska
Department of Otolaryngology
and Laryngological Oncology
Medical University of Lodz
22 Kopcinskiego St
90-153 Lodz, Poland
Phone: +48 602 225 721
E-mail: wioletta.pietruszewska
@umed.lodz.pl

Extracellular deposits of insoluble proteinaceous material giving a starch-like reaction when treated with iodine and sulphuric acid and accumulating in tissue was for the first time described by Rokitansky in 1842 [1]. It was not until 1851 that Virchow applied the term “amyloidosis” to describe this deposition [2]. An amorphous substance called amyloid (insoluble fibril-forming protein) is deposited in extracellular spaces of organs and tissues. Amyloid deposits, under the electron microscope, appear as non-branching fibrils with a cross-linked, β -pleated sheet conformation. They are eosinophilic after haematoxylin–eosin staining and display apple-green birefringence with polarized light when stained with Congo red. Chronic inflammations of bacterial or non-bacterial origin and immunological immune-competent neoplasm cells are examples of factors that induce amyloid fibril biosynthesis. The organs and tissues where amyloid deposits occur become stiff and plastic, having a hyaline-like appearance that leads to a loss of previous function [3].

Amyloidosis is probably caused by rearrangement in the immune system, though its pathogenesis is not still known thoroughly. It is a heterogeneous group of diseases having misfolding of extracellular protein as a common etiological factor. Chronic inflammation with extensive tissue destruction, malignant proliferation of plasmocytes and autoimmune diseases promote expansion of amyloidosis. Various clinical types of amyloidosis have an impact on its natural course, therapy and prognosis. Amyloidosis can be divided into various biochemical forms depending on amyloid deposit type: NH_2 -terminal immunoglobulin fragments or their light chains (AL protein); AA protein originated from serum amyloid A (SAA); transthyretin in senile amyloidosis; amino acid sequences of insulin, glutathione, calcitonin, β_2 -microglobulin in chronic haemodialysed patients, APP protein in Alzheimer disease patients, amylin, natriuretic peptide are exemplary proteins, which can accumulate in the tissue forming amyloid [4–7].

Amyloidosis can be clinically divided into localized or systemic with extremely different clinical course. Kidneys, spleen, liver and heart, but also adrenals, pituitary gland, thyroid and alimentary tract are the organs most frequently affected by systemic amyloidosis. The most significantly involved organ systems are heart and kidneys. Extracellular deposition of amyloid leads to their failure, which constitutes the two leading causes of death of patients with systemic amyloidosis.

There are 25 described biochemical forms of amyloidosis, from among which three types are the commonest in clinical practice [3, 8]. The first of them is AL-amyloidosis (light chain) – most often primary/idiopathic or multiple myeloma-associated. NH_2 -terminal fragment or whole immunoglobulin light chains, derived from a monoclonal population of bone marrow cells, are incorrectly modified and produce amyloid deposits. The second type of amyloidosis – the secondary, acquired or reactive one – is characterized by a defect of precursor protein transformation (acute phase protein – serum amyloid A (SAA)). NH_2 -terminal, unique sequence of non-immunoglobulin protein coexisting with C-reactive protein (CRP) and tumor necrosis factor- α (TNF- α) accelerates the deposition of amyloid in the tissue significantly. Increased serum levels of these factors are usually connected with inflammatory conditions – hence the name of this type of amyloidosis, secondary to infections. It occurs during infectious diseases (such as tuberculosis, bone marrow inflammation, leprosy) or inflammatory states (rheumatoid arthritis, Crohn disease, inflammatory bowel disease, connective tissue disorder). Secondary amyloidosis shows a predilection for the spleen, liver, kidneys, lymph nodes and adrenals. Extensive changes in the vascular system are also possible [4, 9]. The third type of amyloidosis (hereditary) is quite rare and runs in families, and is not connected with other diseases. Particular kinds of neuropathy and cardiomyopathy (neuropathic form) are typical for this type of amyloidosis. Autosomal recessive familial Mediterranean fever is the most common condition in this type. Another is a group of autosomal dominant familial amyloid polyneuropathies [8, 9].

Amyloidosis affecting the head and neck occurs mostly as a localized formation although it is very rare. Therefore often it is diagnosed after surgical treatment on the basis on histopathological findings.

We present the clinical and histopathological properties of 7 cases of head and neck amyloidosis with a long follow-up.

Seven cases of localized amyloidosis in the head and neck region were selected from the files of the Department of Otolaryngology, Medical University of Lodz, and the Department of Otolaryngology, Medical University of Lublin, from 1996 to 2006, that had clinical follow-up available. The following clinical information was reviewed: symptoms at presentation, laboratory results, surgical pathology, operative reports, regarding the development of systemic or multifocal disease, extent of disease, serum or urine electrophoretic studies, bone marrow biopsy, the specific treatment modalities, current status of the disease and the patient. The diagnosis of localized amyloidosis was based on two

criteria: no detected diseases possibly underlying the amyloidosis and deposits of amyloid with evidence of AL type in at least one biopsy site [10].

In all cases haematoxylin-eosin and Congo red stains positive for apple-green birefringence under polarized light were performed to confirm the diagnosis. The examination was completed with immunohistochemistry with antibodies against serum amyloid A and κ and λ light chains of immunoglobulins (DakoCytomation). The visualization of the immunological reactions was performed using the immunoperoxidase method with LSAB/Universal Kit (DakoCytomation). As a chromogen diaminobenzidine (DAB) (DakoCytomation) was used.

Multiple myeloma was excluded by serum M-protein lower than 3.0 g/dl, plasma cells less than 10% of the total number of nucleated cells in the bone marrow and no evidence of osteolytic lesions according to criteria of the International Myeloma Working Group [11].

The patients included 3 men and 4 women aged from 41 to 64 at an average of 48.7 at presentation (median 44, SD 9.03). The location of the amyloid deposits were as follows: amyloidosis was revealed in the tongue in two cases and similarly in the pharynx; single cases of amyloid deposits were located in the larynx, the palatine tonsil and the submandibular gland in this group of patients.

The initial clinical presentation correlated with localization of amyloid tumour in our patients (Table I).

In all cases there were no other laryngological, rhinological or otological symptoms apart from the ones mentioned above. Also the patients had no symptoms referable to the musculoskeletal system with no weight loss, abdominal or cardiac discomfort, with good appetite. All the patients had no radiation or major trauma to their involved site of amyloid tumour. All other laboratory findings, including chest X-ray examination, abdominal ultrasound, electro- and echocardiogram, complete blood cell count, liver and renal function tests, serum and urine protein electrophoresis were normal. Post-operative healing was uneventful in each case. No lymphoproliferative disorder was detected. In a long observation no recurrences were detected in that group of patients (Table I).

Only in patient 7 did further studies confirm systemic amyloidosis. The diagnostic process started with taking an open biopsy from the tongue and then from the rectum to find out if it was a systemic disorder. Despite treatment (prednisone and melphalan), the patient died from circulatory failure within 1 month after the diagnosis and the initial treatment.

On the histological examination the amyloid was presented as extracellular, amorphous, eosi-

Table 1. Characteristics of clinical presentation and findings, treatment and follow-up of investigated patients with amyloidosis

No.	Age [years]	Sex	Initial clinical presentation	Clinical findings	Treatment	Follow-up
1	41	Male	An obstacle in the throat for 1 year	2.0 cm × 2.0 cm flat, nodular lesion in the right palatine tonsil	Unilateral tonsillectomy	Four years, no recurrence
2	43	Female	Two year duration of gradual and progressive enlargement of the right submandibular gland; no associated halitosis or dryness in the mouth or eyes	3 cm × 3 cm tumour in right submandibular gland	Excision of submandibular gland	Five years, no recurrence
3	44	Female	One year hoarseness	Lobulated right true vocal fold with involvement of anterior commissure	Microlaryngotomy	Twelve years, no recurrence
4	59	Female	An obstacle in the pharynx and dysphagia after the infection of the upper respiratory tract a few weeks prior to hospital admission	2.0 cm × 1.0 cm tumour in the midline on the posterior wall of the pharynx	Amyloid tumour excision	Four years, no recurrence
5	43	Male	One year history of an obstacle in the pharynx and dysphagia	A painless and firm 1.5 cm × 1.5 cm tumour located in a midline on the base of the tongue	Partial glossectomy	Eight years, no recurrence
6	47	Male	Decreased hearing in the left ear, nasal obstruction, and postnasal drip for 1.5 years	2.0 cm × 1.0 cm, firm, painless, polypoid tumour attached by the pedicle to the mucous in the region of left choanae and Rosenmüller fossa and reaching the oropharynx	Endoscopic amyloid tumour excision	Ten years, no recurrence
7	64	Female	One year history of progressive enlargement and swelling in the mouth with progressive fatigue, and 5 kg loss of weight	Macroglossia; tongue rubbery on palpation with scalloping along the lateral borders of the tongue due to dental indentations; cutaneous periorbital purpura	Prednisone/melphalan; initially partial glossectomy	The patient died within 1 month of diagnosis and initial treatment

nophilic material on haematoxylin and eosin staining (Figure 1).

It was dispersed throughout the lamina propria, frequently presenting perivascular and periglandular deposition, especially in the submandibular gland. Sparse, mixed infiltration consisted of lymphocytes and mature plasma cells with occasionally foreign-body type multinuclear giant cells present at the periphery of the deposits. Significant

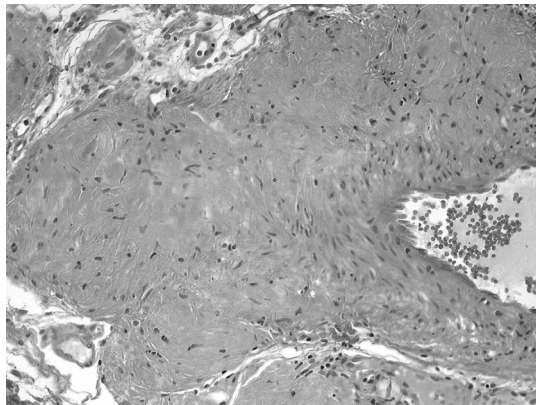


Figure 1. Deposition of amyloid from the tongue in case of systemic AL amyloidosis (H + E staining, magnification 100×)

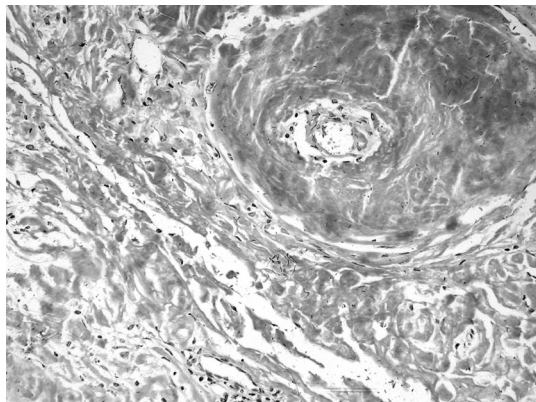


Figure 2. Congo red staining without polarization demonstrating deposition of amyloid in the posterior wall of pharynx tumour (magnification 100×)

cytological atypia of the lymphoplasmacytic infiltrate was not identified.

Apple green birefringence was seen in each case, when sections stained with Congo red were viewed in high intensity polarized light confirming the diagnosis of amyloidosis (Figures 2 and 3).

Immunohistochemical staining for serum amyloid A protein was negative, which indicated non-AA amyloid protein deposition. In each case the amyloid precursor proteins were immunoglobulin light-chain fragments indicating the nature of the amyloid deposits being monoclonal immunoglobulins that confirmed AL-amyloidosis. Lambda chain restriction was present in 6/7 patients whereas κ was found only in 1 patient with nodular amyloid deposition in the nasopharynx (Figure 4).

An extensive search of systemic amyloidosis and multiple myeloma was performed in all patients. Tissue samples from rectum mucous membrane were taken and no amyloid deposits were found in 6/7 patients; only in one patient were the results from both places positive for amyloid deposits. The bone marrow biopsy in patient 7 was negative for myeloma. Electrophoretic separation of urine proteins did not reveal the presence of Bence-Jones protein, which excluded multiple myeloma in 7/7 patients.




Figure 3. Deposits of amyloid displaying characteristic apple-green birefringence by polarized light microscopy (Congo red stain, magnification 100×)

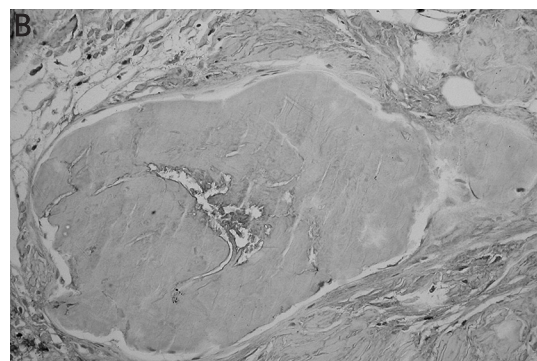
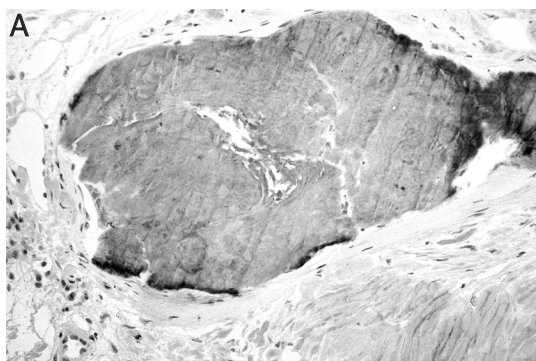


Figure 4. **A** – Positive λ light chain immunohistochemical staining of the amyloid deposit in the pharynx tissue (magnification 400×). **B** – Negative κ light chain immunohistochemical staining in the amyloid deposit in the pharynx tissue (magnification 400×)

Depending on clinical and pathological findings, in 6 cases a form of localized AL amyloidosis was confirmed (patients 1–6). Only in one case (patient 7) was the diagnosis of systemic amyloidosis without multiple myeloma established.

All patients with localized amyloidosis were initially treated with surgical excision of the amyloid mass. Although all of them had long clinical follow-up available (mean 7.16 years, median 6.5, range 4–12, SD 3.37), they are still being regularly followed for 2–3 months without any evidence of local recurrence. One remaining patient with systemic amyloidosis had an unfavourable outcome, which was mentioned above. The exact treatment and follow-up data are summarized in Table I.

Although in the head and neck region amyloid deposition is a rare condition [4, 12], it can be relatively frequent in comparison to other organs. Penner and Muller [8] reported that head and neck amyloidosis accounted for 19% of all amyloid cases. The condition is most often diagnosed between the fourth and sixth decade of life but localized cases occurred earlier than systemic [13]. We observed it also in our group of patients with localized AL with an average age of 48.7 while the patient with systemic AL was 64 years old.

Clinically, amyloidosis can be divided into systemic and localized. However, only 9% to 15% of amyloidosis is of the localized type. There are no characteristic symptoms for amyloidosis in the upper aerodigestive tract. Pain and asymmetry of the lesion are typical for palatine amyloidosis [14]. Patients with amyloidosis of the larynx complain of hoarseness, gradually increasing dyspnoea, haemoptysis and dysphagia [4, 15]. Patient 4, who presented laryngeal amyloidosis, complained only of hoarseness. In most cases, patients with pharyngeal amyloidosis suffer from discomfort in the pharynx – non-specific symptom for amyloidosis. In the case of amyloidosis of Waldeyer's ring patients suffer from an obstacle and discomfort in the throat, likewise patient 2 with an amyloid tumour sited in the right palatine tonsil [16]. In nasopharyngeal localisation patients may present nasal obstruction, epistaxis, postnasal discharge and serous otitis media with effusion. In the presented case only a slight ear problem and postnasal discharge were the symptoms. Therefore, almost in each case with laryngological symptoms, amyloidosis should also be taken into consideration.

In systemic amyloidosis the most frequent symptom in the head and neck region (in 15–20% of cases) is enlargement of the tongue (macroglossia), which has a high association with plasma cell dyscrasias. It was also confirmed in 1 of our patients. The next symptoms in the sequence are cutaneous lesions around the upper eyelid, and local changes in the trachea and larynx, where amy-

loid deposits account for 0.2–1.5% of benign laryngeal tumours [6]. Laryngeal amyloidosis, contrary to the one pertaining to the tongue, is rarely a component of a systemic disease [6, 8, 14, 17, 18]. Other reported sites for localized amyloidosis of head and neck are the thyroid gland, parathyroid gland, eyelid, nasopharynx, paranasal sinus, gingiva, cervical lymph nodes, maxilla, skull base, nasal septum, external ear canal, Waldeyer's ring, parotid gland, and temporal bone [19]. However, they are all rare. Nasopharyngeal amyloidosis, for example, has been reported in the literature to date, with the presented case, only in 14 subjects [20]. The larynx is the most common site affected by localized amyloidosis [4, 8, 21, 22] although in our series only one patient had laryngeal localized amyloidosis. Within the larynx the most common locations are true and false vocal cords, sub- and supraglottis and anterior commissure [13], as we revealed in our patient as well. Localized deposits of amyloid in head and neck usually create single, icicle-like formations with a smooth surface, imitating benign tumours of waxen consistency [8, 16, 17], which in our patients was also reported.

The pathogenic mechanism of localized amyloidosis is still unclear. The biopsy of head and neck localized amyloidosis, contrary to the systemic one, demonstrates the presence of numerous plasma cells and giant cells of histiocytic origin. There is some evidence that monoclonal plasma cells at this location are probably responsible for producing structurally abnormal immunoglobulins with certain amino acid residues occurring at the highly conserved region of the light chain. That could change the configuration of the protein and render them particularly amyloidogenic, which results in localized amyloid formation [3, 13]. The variable region of λ light chain restriction, with greater frequency in the literature, is known to be more amyloidogenic than κ . According to these data most of our patients (6/7) presented λ chain restriction. However, in the Ma *et al.* [13] series, λ chain restriction accounted for 66% of cases.

Nevertheless, the importance of determining whether amyloid deposits represent localized or systemic amyloidosis is pointed out because of the distinctly shortened life expectancy in patients with systemic forms of amyloidosis due to its involvement in vital organs. Patients with systemic AL amyloidosis survive only up to 1 year if untreated [23]. According to the literature each localization, except the larynx, can be associated with haematological malignancies and the plasma cell dyscrasias and amyloidosis may co-exist in the head and neck [8, 14]. Further diagnostic process to exclude systemic amyloidosis is essential when a single focus of amyloid deposits is verified. An invasive biopsy of the gingival mucous membrane, abdominal subcuta-

neous fat, bone marrow or rectal biopsy is currently a very important part of the diagnostic procedure and the most affinitive and specific one, but discrepancies in view of its necessity among authors do exist [16, 23]. The absence of Congo red staining of biopsy specimens from either of two sites (primary tumour and predominantly rectum) indicates that the amyloidosis is not systemic. Specific organ involvement may also be excluded by radiological and laboratory tests. It is necessary to undergo a systemic workup which includes inter alia laboratory tests of the urine in order to exclude Bence-Jones proteinuria, which is pathognomonic for multiple myeloma, and radiological studies to look for a primary tumour in order to exclude B-cell lymphoma [8, 18]. The diagnosis for systemic disease is also crucial in planning the proper treatment [24]. The extensive search for other locations of amyloid deposits was negative in all our patients with localized amyloidosis; only patient 7 with macroglossia was finally diagnosed as having systemic AL amyloidosis.

Unlike systemic amyloidosis, however, localized amyloidosis has an excellent prognosis. In contrast to Alaani *et al.* [4] and Zhuang *et al.* [19], in the available literature only one case of progression from localized to systemic amyloidosis was proved. Penner and Muller [8] revealed development of Hodgkin's lymphoma after 12 years of the initial treatment of localized amyloidosis of the tongue. Cases of local recurrences are described more often [6]. Ma *et al.* [13] and also Penner and Muller [8] reported patients with multiple recurrences of localized amyloidosis, each treated with surgical excisions, using carbon dioxide laser or conventional surgery. In the present data no recurrences of the localized amyloidosis were observed in 4–12 years of a follow-up. Although amyloidosis usually manifests as a slow-growing, benign tumour, it may be locally aggressive and produce osteolysis. Hegarty and Rao [25] and also Patel *et al.* [26] reported cases of the nasopharynx involving the skull base. In these cases computed tomography or magnetic resonance imaging is helpful in revealing any bony destruction or intracranial extension [4, 6]. In computed tomography amyloidosis appears as marked thickening of the soft tissue, whereas in magnetic resonance imaging amyloid deposits have the same signal as skeletal muscle, whilst neoplastic tumour shows a significant degree of contrast enhancement [27].

The mainstay of localized amyloidosis treatment is conservative excision with either an open operation or carbon dioxide laser [4, 21]. Therapy including corticosteroids and radiotherapy has been shown to be ineffective [22]. Treatment of systemic amyloidosis includes prednisone/melphalan (mostly AL form) or prednisone/melphalan/colchicine or

either colchicine monotherapy or with cyclophosphamide (mostly AA form) in order to reduce amyloid precursor protein production and to decrease deposition of amyloid in tissue [8, 15, 28]. Currently, the hope for amyloidosis treatment is a small-molecule drug called CPHPC, which depletes the serum amyloid P (SAP) component, crucial in pathogenesis of amyloidosis. The new drug is a competitive inhibitor of SAP and binds to amyloid fibrils and stabilizes them. Human trials for this molecule are under way [5, 9, 23]. Moreover, the results of molecular findings in patients with amyloidosis can shed new light on the question why different lengths of amyloid fibrils can be responsible for different organ and tissue deposition [29].

Amyloidosis, although a rare disease, is not uncommon. Therefore, in each case of head and neck localized tumour, the need for a detailed and comprehensive patient evaluation cannot be overemphasized. Moreover, the role of a high index of amyloidosis suspicion in evaluating a patient with a head and neck tumour or swelling should be taken into consideration. Also, there is a need for a long close follow-up in all the patients after localized AL amyloidosis treatment due to recurrences.

References

1. von Rokitsansky KF. Handbuch der pathologischen Anatomie. Braumuller&Seidel, Vienna 1842; 209-49.
2. Virchow R. Bav and Zusmmersetzzyng der Corporci Amalacca des Menschen. Vehr Phys Med Geswurzlurg 1851; 2: 51-3.
3. Westermark P. Aspects on human amyloid forms and their fibril polypeptides. FEBS J 2005; 272: 5942-9.
4. Alaani A, Warfield AT, Pracy JP. Management of laryngeal amyloidosis. J Laryngol Otol 2004; 118: 279-83.
5. Pepys MB, Herbert J, Hutchinson WL, et al. Targeted pharmacological depletion of serum amyloid P component for treatment of human amyloidosis. Nature 2002; 417: 254-9.
6. Thompson LD, Derringer GA, Wenig BM. Amyloidosis of the larynx: a clinicopathologic study of 11 cases. Mod Pathol 2000; 13: 528-35.
7. Aisen PS, Gauthier S, Ferris SH, et al. Tramiprosate in mild-to-moderate Alzheimer's disease – a randomized, double-blind, placebo-controlled, multi-centre study (the Alphase Study). Arch Med Sci 2011; 7: 102-11.
8. Penner CR, Muller S. Head and neck amyloidosis: a clinicopathologic study of 15 cases. Oral Oncol 2006; 42: 421-9.
9. Westermark P, Benson MD, Buxbaum JN, et al.; Nomenclature Committee of the International Society of Amyloidosis. Amyloid: toward terminology clarification. Report from the Nomenclature Committee of the International Society of Amyloidosis. Amyloid 2005; 12: 1-4.
10. Yoshida T, Matsuda M, Katoh N, et al. Long-term follow-up of plasma cells in bone marrow and serum free light chains in primary systemic AL amyloidosis. Intern Med 2008; 47: 1783-90.
11. The International Myeloma Working Group. Criteria for the classification of monoclonal gammopathies, multiple

- myeloma and related disorders: a report of the International Myeloma Working Group. *Br J Haematol* 2003; 121: 749-57.
12. Ghekiere O, Desuter G, Weynand B, Coche E. Hypopharyngeal amyloidoma. *AJR Am J Roentgenol* 2003; 181: 1720-1.
13. Ma L, Bandarchi B, Sasaki C, Levine S, Choi Y. Primary localized laryngeal amyloidosis: report of 3 cases with long-term follow-up and review of the literature. *Arch Pathol Lab Med* 2005; 129: 215-8.
14. Pribitkin E, Friedman O, O'Hara B, et al. Amyloidosis of the upper aerodigestive tract. *Laryngoscope* 2003; 113: 2095-101.
15. Chadwick MA, Buckland JR, Mason P, Randall CJ, Theaker J. A rare case of dysphagia: hypopharyngeal amyloidosis masquerading as a post-cricoid tumour. *J Laryngol Otol* 2002; 116: 54-6.
16. Green KM, Morris DP, Pitt M, Small M. Amyloidosis of Waldeyer's ring and larynx. *J Laryngol Otol* 2000; 114: 296-8.
17. Bartels H, Dikkers FG, van der Wal JE, Lokhorst HM, Hazenberg BP. Laryngeal amyloidosis: localized versus systemic disease and update on diagnosis and therapy. *Ann Otol Rhinol Laryngol* 2004; 113: 741-8.
18. Benning S, Technau-Ihling K, Fisch P, Fradis M, Schipper J, Maier W. Amyloid tumor of the larynx associated with plasma cell infiltration: differential diagnosis. *Ear Nose Throat J* 2004; 83: 839-43.
19. Zhuang YL, Tsai TL, Lin TZ. Localized amyloid deposition in the nasopharynx and neck, mimicking nasopharyngeal carcinoma with neck metastasis. *J Chin Med Assoc* 2005; 68: 142-5.
20. Panda NK, Saravanan K, Purushotaman GP, Gurunathan RK, Mahesha V. Localized amyloidosis masquerading as nasopharyngeal tumor: a review. *Am J Otolaryngol* 2007; 28: 208-11.
21. Behranwala KA, Asgar AB, Borges A, Marfatia PT. Laser in treatment of laryngeal amyloidosis. *Ind J Otolaryngol Head Neck Surg* 2004; 56: 46-8.
22. Mitrani M, Biller HF. Laryngeal amyloidosis. *Laryngoscope* 1985; 95: 1346-7.
23. Rajkumar SV, Gertz MA. Advances in the treatment of amyloidosis. *N Engl J Med* 2007; 356: 2413-5.
24. Lebowitz RA, Morris L. Plasma cell dyscrasias and amyloidosis. *Otolaryngol Clin North Am* 2003; 36: 747-56.
25. Hegarty JL, Rao VM. Amyloidoma of the nasopharynx: CT and MR findings. *AJNR Am J Neuroradiol* 1993; 14: 215-8.
26. Patel A, Pambuccian S, Maisel R. Nasopharyngeal amyloidosis. *Am J Otolaryngol* 2002; 23: 308-11.
27. Aydin O, Ustundag E, Iseri M, Ozkarakas SH, Oguz A. Laryngeal amyloidosis with laryngocele. *J Laryngol Otol* 1999; 113: 361-3.
28. Gertz MA, Lacy MQ, Dispenzieri A, et al. Stem cell transplantation for the management of primary systemic amyloidosis. *Am J Med* 2002; 113: 549-55.
29. Pepys MB. A molecular correlate of clinicopathology in transthyretin amyloidosis. *J Pathol* 2009; 217: 1-3.